

Evolution of Class III treatment in orthodontics



Peter Ngan^a and Won Moon^b
Morgantown, WV, and Los Angeles, Calif

Angle, Tweed, and Moyers classified Class III malocclusions into 3 types: pseudo, dentoalveolar, and skeletal. Clinicians have been trying to identify the best timing to intercept a Class III malocclusion that develops as early as the deciduous dentition. With microimplants as skeletal anchorage, orthopedic growth modification became more effective, and it also increased the scope of camouflage orthodontic treatment for patients who were not eligible for orthognathic surgery. However, orthodontic treatment combined with orthognathic surgery remains the only option for patients with a severe skeletal Class III malocclusion or a craniofacial anomaly. Distraction osteogenesis can now be performed intraorally at an earlier age. The surgery-first approach can minimize the length of time that the malocclusion needs to worsen before orthognathic surgery. Finally, the use of computed tomography scans for 3-dimensional diagnosis and treatment planning together with advances in imaging technology can improve the accuracy of surgical movements and the esthetic outcomes for these patients. (*Am J Orthod Dentofacial Orthop* 2015;148:22-36)

In 1899, Angle¹ was the first to classify malocclusions into Class I, Class II, and Class III based on the relationship of the first molars and the alignment (or lack of it) of the teeth relative to the line of occlusion. Almost immediately, it was recognized that the Angle classification was not complete because it did not include important characteristics of the patient's problem. Gradually, Angle's classification numbers were extended to refer to the skeletal jaw relationship and the pattern of growth other than the molar relationship. Thus, a Class III jaw relationship meant that the mandible was positioned mesial to the maxilla. This was usually found in connection with a Class III molar relationship but occasionally could be a Class I molar relationship when the dental compensation overcame the skeletal imbalance. A Class III growth pattern is then defined as one with disproportionate forward mandibular growth or deficient maxillary growth.

In 1966, Tweed² classified Class III malocclusions into 2 categories: category A was defined as a pseudo-Class III malocclusion with a conventionally shaped mandible, and category B was defined as a skeletal Class III malocclusion with a large mandible or an underdeveloped maxilla. Moyers³ further classified malocclusions according to the cause of the problem: osseous, muscular, or dental in origin. Moyers emphasized the need to determine whether the mandible, on closure, is in centric relation or in a convenient "anterior" position for patients with neuromuscular or functional problems. Anterior repositioning generally results from a tooth contact relationship that forces the mandible in a forward position. Moyers suggested that a pseudo-Class III malocclusion is a positional malrelationship with an acquired neuromuscular reflex.

The prevalence of Angle Class III malocclusions varies greatly among and within populations, ranging from 0% to 26%.⁴ Pseudo-Class III malocclusions are found primarily in the deciduous and mixed dentitions. Approximately 60% to 70% of anterior crossbites in the 8- to 12-year-old group were classified as pseudo-Class III malocclusions.⁵ A study excluding children under 11 years old found that the populations from Southeast Asian countries (Chinese and Malaysian) showed the highest prevalence rate of 15.8%.⁶⁻⁹ Middle Eastern nations had a mean prevalence rate of 10.2%.^{10,11} European countries had a lower prevalence rate of 4.9%,^{12,13} and the Indian population showed the lowest prevalence rate of 1.2%.^{8,9,14} In white children,

^aProfessor and chair, Department of Orthodontics, School of Dentistry, West Virginia University, Morgantown, WV.

^bAssociate clinical professor and program director, Section of Orthodontics, School of Dentistry, University of California, Los Angeles, Calif.

All authors have completed and submitted the ICMJE Form for Disclosure of Potential Conflicts of Interest, and none were reported.

Address correspondence to: Peter Ngan, Department of Orthodontics, West Virginia University, 1073 Health Science Center North, PO Box 9480, Morgantown, WV 26506; e-mail, pngan@hsc.wvu.edu.

Submitted, revised and accepted, April 2015.

0889-5406/\$36.00

Copyright © 2015 by the American Association of Orthodontists.

<http://dx.doi.org/10.1016/j.ajodo.2015.04.012>

approximately 57% of the patients with either a normal or a prognathic mandible showed a deficiency in the maxilla.¹⁵ In Asian countries such as Japan, patients were found to have a significantly reduced anterior cranial base, an obtuse gonial angle, and an increased lower anterior face height. Backward rotation of the mandible was necessary to coordinate the occlusion because of the small maxilla.¹⁶

EVOLUTION OF ORTHOPEDIC TREATMENT

In 1728, Fauchard was first to describe the bandeau, an expansion arch consisting of a horseshoe-shaped strip of precious metal to which the teeth were ligated. It was refined by Bourdet, a dentist to the King of France; he was the first to practice “lingual orthodontics,” expanding the arch from the lingual aspect. In 1771, Hunter took a particular interest in the anatomy of the teeth and jaws. His text, *The Natural History of the Human Teeth*,¹⁷ presented the first clear statement of orthopedic principles. He established the difference between teeth and bone, and he gave the teeth names such as cuspidati and bicuspidati. He was the first to describe the growth of the jaws, not as a hypothesis but as a sound, scientific investigation.

In 1802, Fox was the first to give explicit directions for correcting irregularities of the teeth. He was particularly interested in the use of an expansion arch and a chincup. However, it was Kneisel, a German dentist to Prince Charles of Prussia, who was the first to use a removable chin strap to treat patients with a prognathic mandible.

For maxillary orthopedics, Angell was first to open the median palatal suture with a split plate. Case showed remarkable foresight in differentiating between “dental malpositions” and “dentofacial imperfections,” comparable to today’s terms, dentoalveolar and skeletal.¹⁸ He stressed facial esthetics in contrast to Angle’s reliance on occlusion. He said, “The occlusion or malocclusion of the buccal teeth gives no indication of the real position of the dentures in relation to facial outlines.”

ETIOLOGY OF CLASS III MALOCCLUSION

Class III malocclusion can be a result of pure mandibular prognathism or maxillary hypoplasia and retrognathism, or a combination of the two. That means that there is possible anatomic heterogeneity of this type of malocclusion, since either jaw or both jaws can be affected in sagittal length or in position relative to the other. Familial aggregation studies also suggest that familial environmental factors or heredity can play a substantial role in the etiology of Class III malocclusion.¹⁹

Environmental factors that have been thought to influence Class III malocclusion include habits, enlarged tonsils, chronic mouth breathing leading to downward and backward growth of mandible, abnormal tongue and mandibular posture, endocrine disturbances, posture, trauma, and nasal blockage.²⁰ The role of these factors, however, is based on only a few observations.

The familial nature of mandibular prognathism was first reported by Strohmayr in 1937 as noted by Wolff et al²¹ in their analysis of the Hapsburg family. However, it is probable that the mandibular prognathism in the Hapsburg family was heavily influenced by inbreeding, an autosomal recessive pattern, and other multifactorial inheritance possibilities. Analyses of less inbred groups usually indicate an autosomal dominant mode of inheritance with incomplete penetrance and variable expressivity in some families and multifactorial influences in others.¹⁹

TREATMENT OF PSEUDO-CLASS III MALOCCLUSION

A pseudo-Class III malocclusion is characterized by an anterior crossbite caused by a forward functional displacement of the mandible. In the mixed dentition, the patient usually has a mesial step that is less than 3 mm. The maxillary incisors are retroclined, and the mandibular incisors are proclined and spaced.²² When patients are guided into a centric relationship, they often show an end-to-end incisor relationship accompanied by a forward shift of the mandible that we now call a functional Class III malocclusion. In most patients, it is caused by retroclination of the maxillary incisors. Often, there is a Class I molar relationship with a normal mandibular appearance and a straight facial profile, disguising the skeletal discrepancy.

An anterior crossbite and a mild skeletal Class III malocclusion in the mixed dentition can be corrected with a variety of treatment approaches, including removable appliances, partial fixed appliances, orthopedic chincup, and facemask for a short duration. Correction of the anterior crossbite should be carried out as soon as it is detected to maximize the orthopedic effects and the stability of early treatment.^{23,24} Correcting an anterior crossbite increases the maxillary arch perimeter, offering more space for the eruption of the canines and the premolars. Anterior crossbites left untreated have been associated with a variety of complications, such as gingival recession of the mandibular incisors, incisal wear, and worsening of the growth pattern.

Removable functional appliances such as Fränkel III regulators and activators to treat Class III malocclusions

work by permitting the eruption of the maxillary molars and maintaining the mandibular ones in position, leading to an occlusal plane rotation that helps to shift the molar relationship from Class III to Class I.²⁵ On the other hand, maxillary protraction using a facemask creates a counterclockwise rotation of the maxilla and a clockwise rotation of the mandible, usually resulting in increased lower face height.²⁶⁻²⁸ Therefore, these appliances are more suitable to be used in functional Class III patients with lower angles.

In young patients with an anterior crossbite, better results can be achieved through the association of maxillary expansion because of orthopedic stability and the movement of the maxilla down and forward.²⁹ In 84% of patients, self-correction can be expected without the need for any other appliance. The association of maxillary expansion and 2 × 4 fixed appliances improves the arch perimeter, reducing the number of extractions in patients with slight to mild crowding. The increase has been quantified to span up to 6.0 mm in the maxillary arch. Other advantages of fixed appliances include better 3-dimensional (3D) control of tooth movement and the use of light continuous forces.³⁰

TREATMENT OF SKELETAL CLASS III MALOCCLUSION WITH A CHINCUP

In 1836, Kneisel, a German dentist to Prince Charles of Prussia, was the first to use a removable chin strap to treat patients with a prognathic mandible. This was followed by Westcott, who also reported the use of occipital anchorage to correct mandibular protrusion. After a long period of disuse of the vertical chincup, Oppenheim³¹ reintroduced extraoral anchorage in 1944.

The chincup, or chincap, was widely used in the Southeast Asian countries because of the prevalence of Class III patients with mandibular prognathism and downward and backward growth directions. Sugawara et al³² and Mitani et al³³ reported that chincap forces can alter the mandibular form and condylar growth. Deguchi et al³⁴ reported that aggressive application of a chincup or reverse-pull headgear for 2 years resulted in effective orthopedic treatment, and skeletal relapse diminished by 0% to 40% judging by the ramus angle, gonial angle, ANB, and Wits appraisal (Fig 1). However, Sugawara³² and Mitani³³ also admitted that although the mandibular position could be improved anteroposteriorly during the first 2 or 3 years of chincap therapy, the initial changes were not always maintained when chincap use was discontinued before facial growth was complete. Recovery growth may cause recurrence of the prognathic face and Class III malocclusion after discontinuation of chincap therapy. The author

recommended that chincap use must be continued until the completion of facial growth. Chincap therapy is not indicated for patients with a true skeletal Class III malocclusion, a large mandible, a normal anteroposterior maxillary position, a mild anteroposterior skeletal discrepancy, a normal cranial base angle, a normal lower face height, and no temporomandibular joint disorder or indication for surgery.

TREATMENT OF A SKELETAL CLASS III MALOCCLUSION WITH A PROTRACTION FACEMASK

Until 1970, a Class III malocclusion was synonymous with mandibular prognathism. Many studies since then have found that in most patients, the hypoplastic maxilla is often the primary etiology of a Class III malocclusion. Dietrich³⁵ reported maxillary retrusion in 40% of white children. Mandibular prognathism was due in part to positional deviation of the mandible relative to the cranial base. Maxillary retrusion was due primarily to inadequate length of the maxillary base. Guyer et al¹⁵ reported that 57% of white children with either a normal or a prognathic mandible showed a deficiency in the maxilla. On the other hand, Masaki¹⁶ found that patients with Asian origin have a significantly reduced anterior cranial base, an obtuse gonial angle, and an increased lower anterior face height. A backward rotation of the mandible was necessary to coordinate the occlusion because of a small maxilla.

In 1944, Oppenheim,³¹ a native of Moravia (now the Czech Republic), published the records of 3 Class III patients treated with a chincup and spurs, attached via elastics to a soldered maxillary lingual arch. Kettle and Burnapp³⁶ from Guy's Hospital in London, United Kingdom, also used a chincup with spurs to protract the maxilla in patients with cleft lip and palate. Most of us are familiar with the facemask of Delaire,³⁷ which was a modification of the chincup that also incorporated a forehead support and an interlabial bow with spurs for attachment of elastics.

Haas²⁹ reported that maxillary expansion alone often causes the maxilla to advance and drop vertically, rotating the mandible down and back. Using Class III elastics with palatal expansion, Haas demonstrated the correction of mild Class III malocclusions with this approach. In the 1970s, several primate studies contributed to our understanding of the anatomic effects of continuous protraction forces to the maxilla.³⁸⁻⁴¹ These studies demonstrated not only significant maxillary skeletal and dental movements, but also orthopedic changes distant from the maxilla such as in

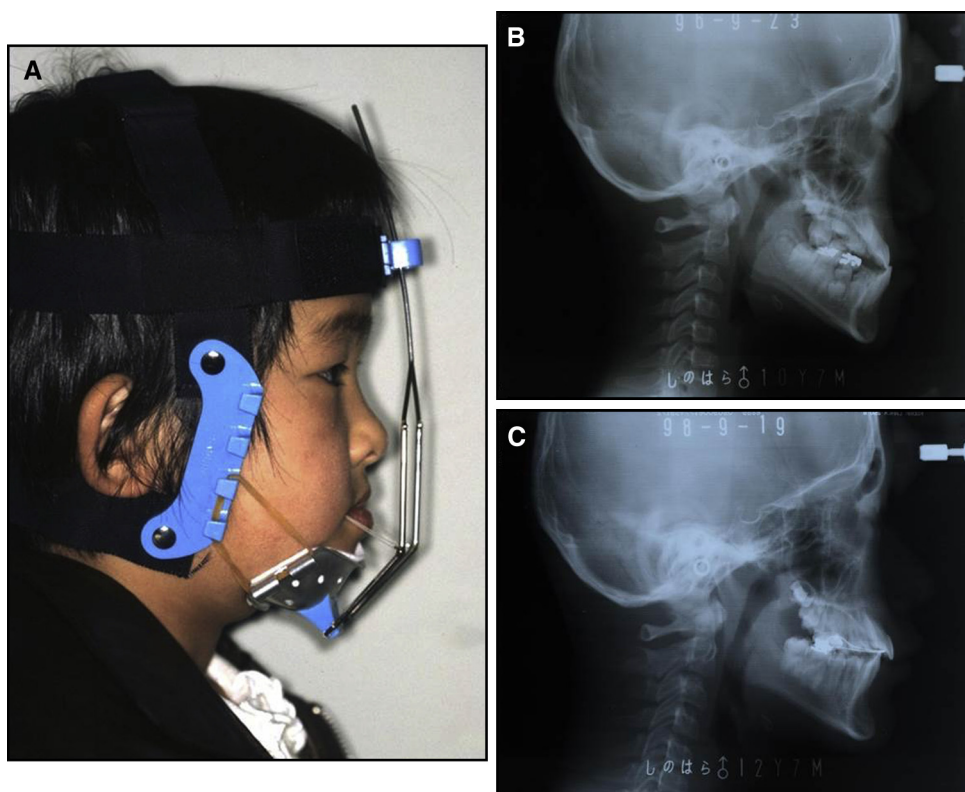


Fig 1. **A**, A chincup or reverse-pull headgear used for 2 years can produce effective orthopedic treatment; **B**, pretreatment lateral cephalogram; **C**, posttreatment lateral cephalogram showing improvement in anteroposterior and vertical growth after treatment.

the zygomaticotemporal articulation and the spheno-occipital synchondrosis.

In 1987, McNamara⁴² presented a case report and used a bonded expansion appliance in conjunction with a facemask to treat Class III patients with maxillary deficiency. This was followed by Turley,⁴³ who presented a young patient with a Class III malocclusion corrected using palatal expansion and custom protraction headgear. Maxillary protraction has also been used in conjunction with an active chincup to produce a more efficient orthopedic treatment for Asian patients with combined maxillary deficiency and mandibular prognathism.⁴⁴⁻⁴⁶

In the 1990s, several scientific studies clarified the effects of maxillary protraction on the correction of Class III malocclusions with maxillary deficiency.^{26-28,47-50} This involves forward movement of the maxilla, downward and backward rotation of the mandible, proclination of the maxillary incisors, and retroclination of the mandibular incisors. These studies also found that the amount of forward movement of the maxilla was limited to 2 to 4 mm, and this effect diminished in older patients. Liou^{51,52} proposed the

use of an expansion-constriction protocol to achieve greater forward movement of the maxilla by distraction of the maxillary sutures. A recent study showed that maxillary expansion using the expansion-constriction protocol resulted in forward movement of the maxilla and a significant increase in upper airway volume.⁵³

Another shortcoming of using a tooth-borne appliance such as a rapid palatal expander for expansion and protraction is the loss of anchorage of the posterior molars and proclination of the maxillary incisors. Cevdanes et al⁵⁴ introduced bone-anchored maxillary protraction, which induced a significantly greater maxillary advancement than did rapid palatal expansion in conjunction with facemask therapy. Mandibular sagittal changes are similar, whereas vertical changes are better controlled by bone-anchored maxillary protraction. Another favorable aspect of bone-anchored maxillary protraction is the lack of clockwise rotation of the mandible and retroclination of the mandibular incisors. Wilmes et al⁵⁵ proposed the use of a hybrid hyrax expansion appliance with the expansion-constriction protocol to reduce the side effects of a conventional expansion appliance.

Several studies investigated the long-term effects in patients who underwent early Class III treatment. Westwood et al⁵⁶ followed a sample of Italian children who underwent rapid palatal expansion with facemask treatment before the pubertal growth spurt (mean age, 8 years 3 months). At the final observation period (mean age, 14 years 10 months), there was a slightly greater increase in midfacial length (1.6 mm) in the treatment group than in the controls. The overall increase in mandibular length was 2.4 mm less in the rapid palatal expansion with a facemask group than in the controls, and mandibular projection relative to nasion perpendicular was 3.0 mm less in the treated group. The change in the Wits appraisal was 3.4 mm compared with -2.7 mm in the untreated controls. It appears that the favorable skeletal change observed over the long term is due almost entirely to the orthopedic correction achieved during the rapid palatal expansion with a facemask protocol. During the posttreatment period that includes the pubertal growth spurt, craniofacial growth in the patients in the rapid palatal expansion with a facemask group is similar to that of the untreated Class III controls. The authors recommended aggressive overcorrection of the Class III skeletal malocclusion, even toward a Class II occlusal relationship; this appears to be advisable, with the establishment of positive overbite and overjet relationships essential to the long-term stability of the treatment outcome.

Another study was carried out in a prospective clinical trial of 30 Chinese patients with Class III malocclusion and maxillary retrusion; they were treated with rapid palatal expansion with a facemask in the mixed dentition.²⁶ Four years after removal of the appliances, 70% of these patients maintained a positive overjet.²⁷ In an 8-year follow-up study, there were 9 dropouts from the original subjects.²⁸ When the remaining subjects were divided into a stable group and a relapse group, 2 of 3 patients maintained a positive overjet 8 years after active treatment. The immediate treatment outcome in the sagittal plane was the same for both groups, but the lower face height increased and the mandibular plane opened more in the relapse group. Eight years after active treatment, dental compensation was similar in both groups, but the mandible outgrew the maxilla by 4 times in the relapse group, compared with 2 times in the stable group. These results indicate that in a Chinese population, of young patients diagnosed with a maxillary deficiency and treated with a facemask, there is a potential risk that a third of these patients may be candidates for orthognathic surgery later in life because of an unfavorable growth pattern.

For white children with Class III malocclusions, a retrospective study conducted at West Virginia

University included 46 patients of North American origin who received early orthopedic-orthodontic treatment and comprehensive fixed appliance therapy.⁵⁷ Lateral cephalograms were taken at the start of phase 1 of treatment (mean age, 8.6 ± 1.3 years) and at the end of fixed appliance therapy followed by a period of retention (mean age, 16.6 ± 2.8 years). The sample was divided into a stable group (26 patients) with positive overjet and an unstable group (20 patients) with end-to-end or negative overjet. No significant differences were found in the pretreatment craniofacial morphologies between the 2 starting groups. At the end of the observation period, the subjects in the unstable group had smaller Wits appraisal values and saddle angles (N-S-Ar), larger effective mandibular lengths (Co-Pg) and gonial angles (Ar-Go-Me), longer lower anterior facial heights, more anteriorly positioned mandibular molars relative to the maxillary molars, and more retroclined mandibular incisors. The results indicated that despite the lack of differences in craniofacial morphology at an early age, several craniofacial variables can be used over time to determine whether a white Class III patient will have a favorable or an unfavorable treatment outcome.

WHERE DO WE GO FROM HERE?

A new breed of rapid palatal expanders incorporating microimplants—microimplant-assisted rapid palatal expanders—was born as implant orthodontics became popular. Numerous microimplant-assisted rapid palatal expanders were developed independently by investigators, varying in their designs and activation protocols.⁵⁸⁻⁶¹ Carlson et al⁶¹ reported the expansion of surrounding structures including the zygoma when a particular type of microimplant-assisted rapid palatal expander, a maxillary skeletal expander, was used. When using a maxillary skeletal expander, disarticulation of the perimaxillary sutures was noted (Fig 2). Combining maxillary protraction with maxillary skeletal expander was attempted by Moon,⁶² and the findings were reported in numerous international scientific meetings since 2008. When a maxillary skeletal expander was combined with maxillary protraction with a facemask, the following changes occurred: the magnitude of maxillary protraction was much greater than with the conventional approach, almost as much correction as normally achieved by surgical treatment; maxillary protraction for patients in the early teenage years was also possible; unwanted dentoalveolar changes such as proclination of the maxillary incisors were not apparent, and, in some patients, the dental compensations corrected themselves as the skeletal relationship improved;

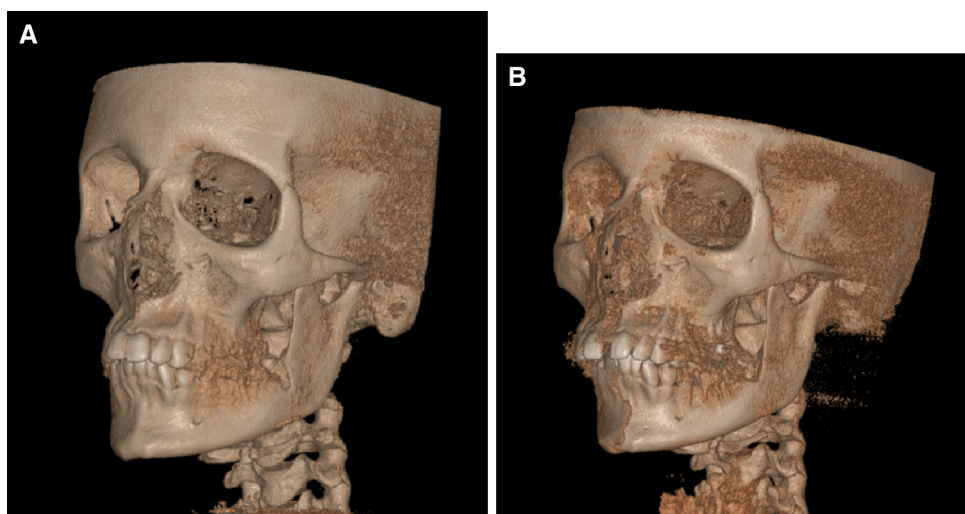


Fig 2. **A,** Pretreatment 3D image; **B,** Posttreatment 3D image after treatment with maxillary skeletal expander, illustrating disarticulation of perimaxillary sutures and its impact on surrounding structures.

lateral tipping of the maxillary posterior dentition during maxillary expansion and anterior tipping of maxillary posterior dentition during maxillary protraction were minimal; and subsequently, clockwise rotation of the mandible was rarely observed even in high-angle patients.^{62,63} Others also reported varying degrees of success from combining various bone anchors and facemasks.^{53,63-65}

The maxillary skeletal expander disarticulates all perimaxillary sutures and impacts all structures surrounding the maxilla (Fig 2). When a facemask is combined with it, the protraction force moves the maxilla in a distraction-like fashion. This may be why the magnitude and the speed of protraction exceed previously reported results with the conventional protraction approach.⁶¹⁻⁶³ Wu et al⁶⁶ suggested that adverse dental movements associated with tooth-borne devices are largely eliminated because the expansion and protraction with the maxillary skeletal expander is bone-borne. When skeletal balance was achieved by maxillary skeletal protraction, the maxillary dentition decompensated to a more normal position. This observation is supported by the functional matrix theory.⁶⁷⁻⁷² Dental tipping during expansion and protraction is associated with clockwise rotation of the mandible, especially in high-angle patients. The maxillary skeletal expander and facemask combination can minimize such adverse effects and is recommended for high-angle patients.

De Clerck et al⁷³ reported successfully treated Class III patients by placing maxillary and mandibular bone plates and using Class III elastics with an orthopedic

force level. More favorable patient compliance compared with the facemask treatment approach can be expected. The dentoalveolar side effects were eliminated, as with the maxillary skeletal expander and facemask, and no deformations in the vertical dimensions were found, even though the force vector was more vertical.⁷⁴ One disadvantage was the necessity for surgical placement and removal of the bone plates.

The natural progression of maxillary protraction will be combining the advantages of the novel protraction concepts. The maxillary skeletal expander and the facemask provide the most satisfactory results but require extremely dedicated patients who are willing to wear a facemask. Bone plates and elastic approaches require less patient cooperation, but surgeries are necessary. Developing nonsurgical skeletal anchorage for the mandible and applying orthopedic elastic force against the maxillary skeletal expander were proposed by Moon⁶² at the World Implant Orthodontic Conference in 2011 in Verona, Italy. Three in-vitro studies about developing self-drilling and self-tapping microimplants for orthopedic forces have been reported recently by Hong et al^{75,76} and Song et al,⁷⁷ and the results were promising.

CAMOUFLAGE CLASS III TREATMENT IN NONGROWING CLASS III PATIENTS

Nongrowing patients with a skeletal Class III malocclusion are of great interest to practicing orthodontists. The choice between camouflage treatment

and orthognathic surgery remains a challenge to the specialty. Class III patients who decline orthognathic surgery have been aggressively treated using multibrackets with Class III elastics, extractions, and multiloop edgewise archwire therapy.

Class III elastics or extraoral cervical anchorage (J-hook headgear) applied to the mandibular teeth can be used to retract the mandibular teeth and control the bite depth, but it requires patient cooperation.⁷⁸ In addition, Class III elastics may inadvertently affect the inclination of the occlusal plane, the interincisal relationship, and the temporomandibular joint. These undesirable side effects can produce downward and backward rotation of the mandible, proclination of the maxillary incisors, and extrusion of the maxillary molars. These changes can lead to an unpleasing esthetic profile and instability during retention.

The multiloop edgewise archwire technique has many loops with second-order bends to control the vertical movements of the posterior teeth.⁷⁹ It controls the movement of individual teeth and transmits the force produced by Class III elastics. The entire mandibular arch can be distalized and uprighted by a combination of the multiloop edgewise archwire technique and intermaxillary elastics. This combined effect induces a counterclockwise rotation of the occlusal plane, without significant downward and backward rotation of the mandible. This technique is particularly helpful for patients with increased lower face height or an open-bite tendency. However, the open bite can become worse without patient cooperation with elastics.

Extraction of mandibular teeth is occasionally indicated for patients with a moderate Class III skeletal malocclusion and may include extraction of the first premolars or incisors. Extraction of a mandibular incisor is occasionally indicated for patients with an anterior crossbite or an edge-to-edge incisor relationship. The decision is determined by factors such as the severity of anterior crowding in the mandibular arch, the Bolton discrepancy, and the degrees of negative overjet and overbite.

The use of temporary anchorage devices such as microimplants for anchorage has opened up a variety of options for the treatment of Class III patients.²⁸ In contrast to extraoral anchorage or intermaxillary elastics, the use of temporary anchorage devices as anchorage does not require patient cooperation; these devices simplify the treatment mechanics, reduce the amount of archwire bending, and minimize the loss of anchorage. For treatment of Class III malocclusions, microimplants can be placed in the mandibular or maxillary dentition. For retraction of the mandibular dentition, microimplants can be placed in the retromolar area or

the interradicular space between the mandibular first molars and the second premolars, or between the first and second molars. Intra-arch elastics or coil spring is attached to the microimplants, and the entire mandibular arch can be distalized or uprighted with minimal movement of the maxillary dentition. Microimplants can be placed more anteriorly in the maxillary arch and used for en-masse protraction when anterior movement of the maxillary dentition is allowed. The relatively small interradicular space in this area may not allow a large amount of protraction. Placing microimplants apically allows for more movement. The microimplant can also be placed in the anterior palate, and the protraction can be performed from the palatal side. Buccal protraction produces a moment in the outward direction, causing the arch to expand, and palatal protraction produces a moment in the opposite direction, causing arch constriction. Combining palatal and buccal protractions is most efficient, creating a moment and a counter-moment in the occlusal plane and, in turn, canceling their side effects. Combining a microimplant with a multiloop edgewise archwire to eliminate the patient compliance factor has been reported to be effective.⁸⁰ In addition, patients with Class III problems and facial asymmetry can be treated with temporary anchorage devices to resolve dental problems followed by orthognathic surgery to resolve the remaining skeletal problems.

Improving Anchorage for Camouflage Class III Treatment

Camouflaging became more predictable with microimplants; consequently, more severe Class III problems can be treated.⁸¹ These difficult cases pose great challenges because treatment duration proportionally increases with the level of severity. Sakthi et al⁸² reported creating a regional acceleratory phenomenon during the en-masse distalization, and it increased the speed of tooth movements. Average rates of space closure of 1.8 mm per month in the maxilla and 1.57 mm per month in the mandible were observed in the study group compared with 1.02 mm per month in the maxilla and 0.87 mm per month in the mandible in the control group during the first 2 months. Combining regional acceleratory phenomenon creation and a microimplant anchor system may help in achieving satisfactory results with a shorter treatment time. Extraction of the mandibular third molars immediately before distalization can create a regional acceleratory phenomenon and assist in speedy tooth movements. Puncturing cortical bone in localized areas during microimplant-assisted retraction can potentially create a regional acceleratory phenomenon. However, microimplant failure can occur when a

regional acceleratory phenomenon is created near the microimplants, and careful operation is essential. Other means of creating accelerated tooth movement, such as laser treatment, vibration, and a pharmaceutical approach, during retraction and protraction of the mandibular and maxillary dentition have been proposed. Although these concepts are promising, more scientific evidence is needed.

When microimplants are used as anchors during retraction and protraction of the mandibular and maxillary dentition, caution must be used not to displace the dentition beyond the alveolar housing. It is tempting to camouflage more severe patients with microimplants because of the mechanical advantages that this absolute anchorage system provides; however, the biologic limitations should be considered, and surgical treatment might be an option.

SURGICAL TREATMENT OF CLASS III MALOCCLUSIONS

Surgery for mandibular prognathism began early in the 20th century, with occasional treatment that consisted of a body ostectomy, removing a molar or a premolar and an accompanying block of bone. Edward Angle, commenting on a patient who had treatment of this type over 100 years ago, described how the result could have been improved if orthodontic appliances and occlusal splints had been used. Although there was gradual progress in techniques for setting back a prominent mandible throughout the first half of this century, the introduction of the sagittal split ramus osteotomy in 1957 marked the beginning of the modern era in orthognathic surgery.⁸³ This technique used an intraoral approach, which avoided the necessity of a potentially disfiguring skin incision. The sagittal split design also offered a biologically sound method for lengthening or shortening the mandible with the same bone cuts, thus allowing treatment of a mandibular deficiency or excess.

During the 1960s, American surgeons began to use and modify techniques for maxillary surgery that had been developed in Europe, and a decade of rapid progress in maxillary surgery culminated in the development of the LeFort I down-fracture technique that allowed repositioning of the maxilla in all 3 planes of space.⁸⁴ By the 1980s, it was possible to reposition either jaw or both jaws, move the chin in all 3 planes of space, and reposition the dentoalveolar segments surgically as desired. In the 1990s, rigid internal fixation greatly improved patient comfort by making immobilization of the jaws unnecessary, and a better understanding of typical patterns of postsurgical changes made surgical

outcomes more stable and predictable. With the introduction of facial distraction osteogenesis around the turn of the century and its rapid development since then, greater jaw movements and treatment at an earlier age became possible for patients with the most severe problems (usually related to syndromes).

Surgical Class III patients usually have a shorter anterior and posterior cranial base, a smaller saddle angle, and a shorter maxillary length, but a normal maxillary position and a longer mandibular length. In addition, these patients usually exhibit an increase in lower face height and a larger gonial angle, more protrusive maxillary incisors, upright mandibular incisors, and a retrusive upper lip. Cone-beam computed tomography can be used to better understand the morphology of surgical Class III patients. It allows spatial images of the craniofacial structures to be produced, and the images can be observed independently by adjusting the image density of the organs. Reproducible landmarks have been identified along with reference planes. From the frontal computed tomography image, the canting of the maxilla can be detected with reference to the horizontal reference plane. When viewed from the bottom up, the rotation of the maxilla can be seen with reference to the midsagittal plane. Divergence of the nasal plane from the mandibular plane can be noted. The gonial angle can be checked to determine whether it contributes to the deviation of the menton. In addition, advances in imaging technology have enabled the use of a precise measuring tool based on a single-wave moiré imaging technique for multidimensional movement, stereophotogrammetry, 3D computed tomography, and a charge-coupled device camera for 3D analyses. Soft tissue change to hard tissue movement can be calculated.

Conventional surgical movement for Class III treatment

The mandible can be moved forward or back, rotated, and moved down anteriorly to increase the mandibular plane and anterior face height. It can be narrowed anteriorly but widened only with distraction osteogenesis. In patients with compromised airways, mandibular setback can sometimes restrict the airway further. Subapical segmental osteotomy can be considered for these patients.

The maxilla can be moved up and forward with excellent stability, moved down with difficulty because of instability, and moved back only with great difficulty because of all the structures behind it that are in the way. Fortunately, protruding anterior teeth can be moved back via segmental osteotomy, so there is no reason to move the posterior maxilla back. Segmental

osteotomy also allows the maxilla to be widened or narrowed, but widening it also tends to be unstable because of the pull of the stretched palatal tissues.

In the treatment of Class III patients, the maxilla remains just where it was put in about 80% of patients, and there is almost no tendency for major relapse (4 mm or more). With rigid fixation, the combination of maxillary advancement and mandibular setback is acceptably stable. In contrast, isolated mandibular setback is often unstable. Condylar sagging during the mandibular surgery is common because the patient is in a supine position during the surgery, and the condyles sag posteriorly in their sacs. The condyles reposition after intermaxillary fixation is removed, and the mandible moves anteriorly, mimicking surgical relapse. This is also true for downward movements of the maxilla that create downward-backward rotations of the mandible. For this reason, almost all Class III patients now have maxillary advancement, either alone or (more frequently) combined with mandibular setback.

Distraction osteogenesis

This technique is based on manipulation of a healing bone, stretching an osteotomized area before calcification has occurred to generate the formation of additional bone and investing soft tissues.⁸⁵ For correction of facial deformities, this treatment modality has 2 significant advantages: (1) greater distances of movement are possible than with conventional orthognathic surgery, and (2) deficient jaws can be increased in size at an earlier age. The great disadvantage is that precise movements are not possible. With distraction, the mandible or the maxilla can be moved forward, but there is no way to position the jaw or teeth in exactly a pre-planned place, as can be done routinely with orthognathic procedures.

Distraction osteogenesis was frequently performed in growing Class III patients with maxillary dysplasia. Overcorrection was recommended to preclude relapse. Different types of external and internal distractors are available. Extraoral distractors have the capacity for multidirectional maxillary advancement, and the vectors can be changed during the process. However, patient acceptance and accidental trauma are quite frequent. The rigid external distraction device is fixed to the cranium.⁸⁶ This allows for protection of the maxillary teeth compared with other types of extraoral devices that are anchored to the maxilla. The relapse of maxillary advancement with the rigid external distraction device was reported to be 22% after 3 years.⁸⁷ Recently, Iida et al⁸⁸ developed an intraoral distractor to selectively move a segment of the maxilla forward

to prevent velum insufficiency in cleft lip and palate patients (Fig 3).

Surgically assisted rapid palatal expander

Although “Class III” is a term representing the anteroposterior relationship between the maxilla and the mandible, the skeletal discrepancy also exists in the transverse dimension. Maxillary expansion is more often than not a necessary step in Class III correction. As mentioned above, widening of the maxilla by segmental osteotomy is not stable, especially when a large amount of expansion is required. Similar to distraction, a surgically assisted rapid palatal expander can provide greater expansion movement and stability than a segmental osteotomy. A segmental osteotomy detaches the maxilla and segments it into pieces, whereas the maxilla is intact with the surgically assisted rapid palatal expander. The lateral corticotomy is performed, the maxillo-sphenoid junction is disarticulated, the septum is severed, the lateral nasal wall is cut, and the midpalatal suture is split. A palatal jackscrew is used to rapidly expand the maxilla. This procedure is usually done during the presurgical decompensation phase of treatment. Expanding the maxillary arch during this phase has a decisive advantage in eliminating incisor flare for nonextraction patients. When a segmental osteotomy is planned, it is difficult to decompensate anteriorly flared incisors. Extraction of the maxillary premolars or surgical uprighting of the anterior segment may be necessary. Although surgically assisted rapid palatal expansion is a relatively minor surgical procedure, the patient will be subjected to 2 separate surgeries.

Microimplant-assisted rapid palatal expansion for adults

Attempts were made to expand adult maxillae non-surgically by a number of investigators in recent years. Carlson et al⁶¹ and Farret and Benitez⁸⁹ reported positive results. Microimplant-assisted rapid palatal expansion simulates surgically assisted rapid palatal expansion without surgery, but the expansion is not as rapid and requires significantly more force. Because the lateral force loading is closer to the resisting structures especially when the maxillary skeletal expander type of microimplant-assisted rapid palatal expansion device is used,⁶¹⁻⁶³ the expansion is more parallel from the frontal view compared with surgically assisted rapid palatal expansion.⁶⁰ The force loading for surgically assisted rapid palatal expansion is at the molars, and more expansion is observed at the lower part of maxilla, which in turn can cause bite opening.⁹⁰⁻⁹² In high-angle

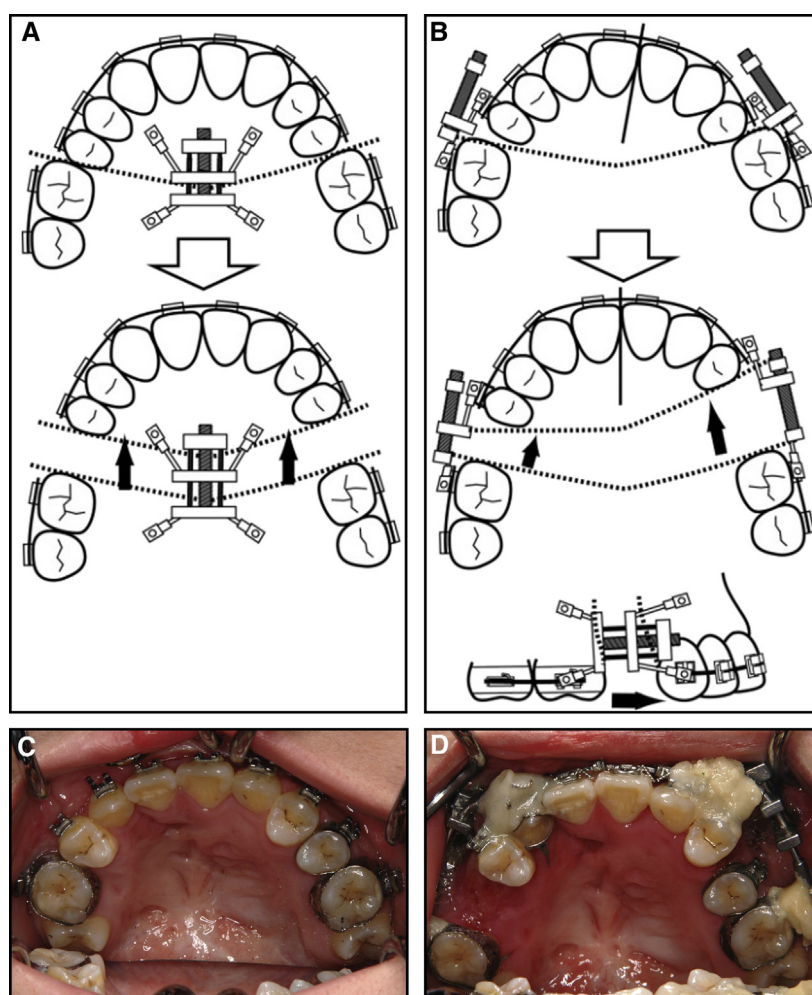


Fig 3. A and B, Schematic diagram showing movement of the maxillary segment with an intraoral distractor. C and D, Intraoral photographs showing changes of the maxillary segments after treatment with an Intraoral distractor.

patients, clockwise rotation can be managed better with the maxillary skeletal expander.

Surgically assisted and microimplant-assisted rapid palatal expansion

When surgically assisted rapid palatal expansion and microimplant-assisted rapid palatal expansion are combined, the advantages of 2 systems can be cumulative. The expansion can be rapid and relatively parallel, preventing unwanted lateral rotation of the maxillary halves.⁶⁰

Early maxillary advancement

Early advancement of a sagittally deficient maxilla or midface remains relatively stable if there is careful attention to detail and grafts are used to combat relapse, but further forward growth of the maxilla is quite unlikely.

Subsequent growth of the mandible is likely to result in reestablishing the Class III malocclusion and a concave profile. The patient and parents should be cautioned about the possible need for a second stage of surgical treatment later. In general, maxillary advancement should be delayed until after the adolescent growth spurt, unless earlier treatment is needed for psychosocial reasons.

Although surgery to reposition the entire maxilla may affect future growth, this is not necessarily the case for the surgical procedures used to correct cleft lip and palate. In cleft patients, bone grafts to alveolar clefts before eruption of the permanent canines can eliminate the bony defect; this greatly improves the long-term prognosis for the dentition. A review of cleft palate patients treated with the Oslo protocol⁹³ (closure of the lip and hard palate at 3 months, posterior palatal closure at 18 months, and cancellous alveolar bone grafting at 8 to

11 years) showed no interference with the total amount of facial growth. As surgery methods for initial closure of a cleft palate continue to improve, the number of cleft patients who need maxillary advancement as a final stage of treatment should decrease.

WHAT IS NEW FOR SURGICAL TREATMENT OF CLASS III PATIENTS?

Surgery first

With the conventional approach, dental decompensation precedes the surgery to ensure that adequate surgical movements can be possible. This procedure assists in producing a predictable and precise final outcome. However, this process sometimes can take 1 year or more, and the patient's occlusion often becomes gradually worse as the dentition moves to a more optimal position in each jaw, but not necessarily occluding well with opposing counterparts. The patient may experience difficulty functionally as well as psychosocially during this phase of treatment. Orthodontic movements can be difficult because of battling the adverse functional environment. The patient's function and facial harmony improve instantly after surgery.

To avoid this part of the treatment, some have promoted a surgery-first procedure in recent years.^{94,95} The obvious advantages are a short preparation period and a subsequently shorter total treatment duration, psychosocial benefits, and rapid creation of a favorable functional environment for orthodontic movement. However, there are some disadvantages with this method. It is difficult to match the dentition without proper orthodontic decompensation before surgery, especially when dental alignments do not coordinate well between the 2 arches. A wafer is often used for jaw positioning, and precise prediction of postsurgical orthodontic movements followed by accuracy in wafer fabrication is critical. It is also easy to underestimate the magnitude of surgery required for the best skeletal harmony. The position where the teeth fit the best generally does not produce optimal jaw positions without orthodontic decompensation. Careful surgical planning for proper jaw position allowing for postoperative orthodontic decompensation is essential. For patients requiring mild to moderate amounts of decompensation, this technique is favorable. On the other hand, those requiring major postoperative orthodontic movement probably should be treated with a conventional approach.^{96,97}

Three-dimensional analysis of Class III malocclusion

To understand the morphology of skeletal Class III patients and develop a better diagnostic tool for surgery,

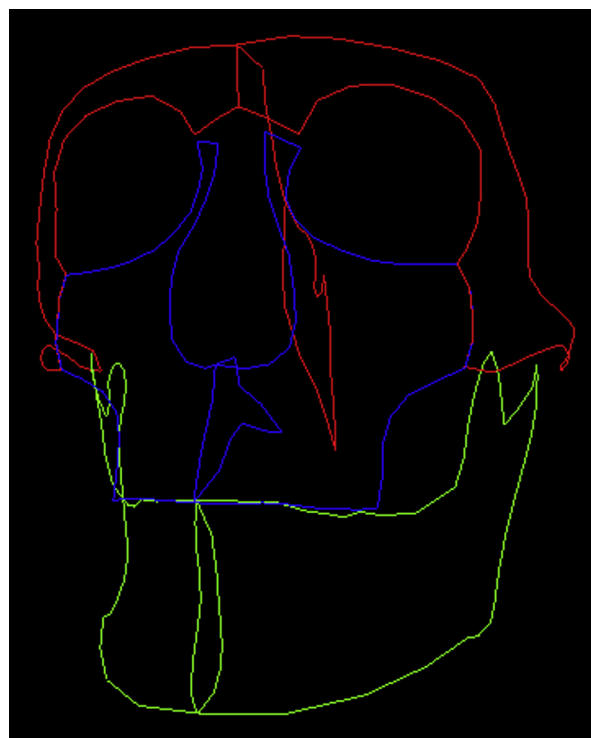


Fig 4. This image represents a colorized displacement map generated by superimposing 1 skull on the 10-skull average. Elliptical Fourier descriptors are useful in quantifying complex 3D structures. *Red*, 10-patient average of cranial base and zygoma; *blue*, 10-patient average of maxillary complex; *green*, 10-patient average of mandible.

3D computed tomography can be used to overcome the limits of a 2-dimensional lateral cephalogram. Park et al⁹⁸ proposed 19 reproducible landmarks along with a horizontal reference plane parallel to the Frankfort horizontal plane, the midsagittal plane, and the coronal reference plane, as well as several linear and angular measurements for diagnosing patients with craniofacial deformity in 3 dimensions.

There have been advances in image analysis as 3D diagnosis and treatment planning have become desirable. Landmark-independent and nonlinear measurement approaches have been explored by several investigators.⁹⁸⁻¹⁰⁰ Boundary analysis such as elliptical Fourier descriptors¹⁰⁰⁻¹⁰³ (Fig 4) and surface mapping functions¹⁰⁴ (Fig 5) are particularly useful in quantifying complex 3D structures. These approaches provide more intuitive and accurate spatial representations of craniofacial morphology than do landmark-based linear and angular measurements. Three-dimensional surgical planning with these systems can greatly aid in complex surgical cases: craniofacial syndromes, asymmetric problems, and so on. Precise fabrication of the surgical

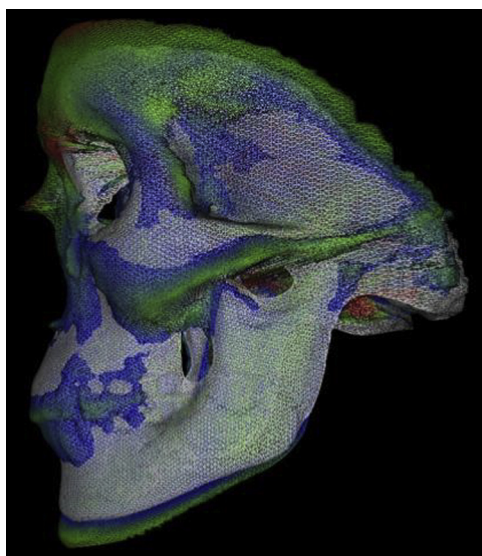


Fig 5. The surface-mapping function is useful in quantifying complex 3D structures. This image represents a colorized displacement map generated by superimposing 1 skull on the 10-skull average. The 10-skull average is represented in *white*, and a sample patient skull is represented in multiple colors. Points of minimal surface variation are illustrated in *blue*, while points of greater variation are seen in *green*.

wafer is also possible using 3D imaging software and a 3D printer. Surgery can now be performed digitally with 3D software, and the projected outcome can be printed on a 3D printer before the actual surgery. This new advancement in 3D technology provides accurate and predictable results.¹⁰⁵

Recent advances in imaging technology also enable clinicians to analyze soft tissues in 3 dimensions using the moiré stripe, stereophotogrammetry, 3D computed tomography, and a charge-coupled device camera. Lin and Lo¹⁰⁶ proposed reproducible soft tissue landmarks of facial structures using a laser scanner.

The surface-mapping function discussed above can be applied to soft tissue images for more comprehensive quantifications.¹⁰⁷ Soft tissue adaptation with surgical correction in 3 dimensions should be further explored using the sophisticated quantification system described earlier. Unlike hard tissues such as the skull, soft tissues add another dimension to quantification because they involve dynamic motions such as facial expressions. Until now, static 2-dimensional photos were used to evaluate smiles and other facial expressions. We now have 3D video capability that requires 4-dimensional quantification. Facial expression changes with Class III surgical correction may be possible to quantify soon.

REFERENCES

1. Angle EH. Classification of malocclusion. *Dent Cosmos* 1899;41:248-64.
2. Tweed CH. Clinical orthodontics. St Louis: Mosby; 1966. p. 715-26.
3. Moyers RE. Handbook of orthodontics. 4th ed. Chicago: Year Book Medical Publishers; 1988. p. 410-5.
4. Hardy DK, Cubas YP, Orellana MF. Prevalence of Angle Class III malocclusion: a systematic review and meta-analysis. *Open J Epidemiol* 2012;2:75-82.
5. Lin JJ. Prevalences of malocclusion in Chinese children age 9-15. *Clin Dent* 1985;5:57-65.
6. Lew KK, Foong WC, Loh E. Malocclusion prevalence in an ethnic Chinese population. *Aust Dent J* 1993;38:442-9.
7. Tang EL. Occlusal features of Chinese adults in Hong Kong. *Aust Dent J* 1994;13:159-63.
8. Woon KC, Thong YL, Abdul Kadir R. Permanent dentition occlusion in Chinese, Indian and Malay groups in Malaysia. *Aust Dent J* 1989;11:45-8.
9. Soh J, Sandham A, Chan YH. Occlusal status in Asian male adults: prevalence and ethnic variation. *Angle Orthod* 2005;75:814-20.
10. El-Mangoury NH, Mostafa YA. Epidemiologic panorama of dental occlusion. *Angle Orthod* 1990;60:207-14.
11. Behbehani F, Artun J, Al-Jame B, Kerosuo H. Prevalence and severity of malocclusion in adolescent Kuwaitis. *Med Princ Pract* 2005;14:390-5.
12. Sidlauskas A, Lopatiene K. The prevalence of malocclusion among 7-15-year-old Lithuanian children. *Medicina (Kaunas)* 2009;45:147-52.
13. Perillo L, Masucci C, Ferro F, Apicella D, Baccetti T. Prevalence of orthodontic treatment need in southern Italian schoolchildren. *Eur J Orthod* 2010;32:49-53.
14. Gauba K, Ashima G, Tewari A, Utreja A. Prevalence of malocclusion and abnormal oral habits in North Indian rural children. *J Indian Soc Pedod Prev Dent* 1998;16:26-30.
15. Guyer EC, Ellis EE 3rd, McNamara JA Jr, Behrents RG. Components of Class III malocclusion in juveniles and adolescents. *Angle Orthod* 1986;56:7-30.
16. Masaki F. The longitudinal study of morphological differences in the cranial base and facial structure between Japanese and American whites. *J Jpn Orthod Soc* 1980;39:436-56.
17. King R. John Hunter and the natural history of the human teeth: dentistry, digestion, and the living principle. *J Hist Med Allied Sci* 1994;49:504-20.
18. Asbell MB. A brief history of orthodontics. *Am J Orthod Dentofacial Orthop* 1990;98:206-13.
19. Otero LM, Morford LA, Falcao-Alencar G, Hartsfield JK. Family history and genetics of mandibular prognathism. In: Ngan PW, Deguchi T, Roberts EW, editors. Orthodontic treatment of Class III malocclusion. Sharjah, United Arab Emirates: Bentham Science; 2014. p. 3-24.
20. El-Gheriani AA, Maher BS, El-Gheriani AS, Sciote JJ, Abu-Shahba FA, Al-Azemi R, et al. Segregation analysis of mandibular prognathism in Libya. *J Dent Res* 2003;82:523-7.
21. Wolff G, Wienker TF, Sander H. On the genetics of mandibular prognathism: analysis of large European noble families. *J Med Genet* 1993;30:112-6.
22. Rabie AB, Gu Y. Orthodontics: management of pseudo Class III malocclusion in southern Chinese children. *Br Dent J* 1999;186:183-7.
23. Wiedela AP, Bondemark L. Stability of anterior crossbite correction: a randomized controlled trial with a 2-year follow-up. *Angle Orthod* 2015;85:189-95.

24. Anderson I, Rabie AB, Wong RW. Early treatment of pseudo-class III malocclusion: a 10-year follow-up study. *J Clin Orthod* 2009; 43:692-8.
25. Giancotti A, Maselli A, Mampieri G, Spanò E. Pseudo-Class III malocclusion treatment with Balters' bionator. *J Orthod* 2003; 30:203-15.
26. Ngan P, Hägg U, Yiu C, Merwin D, Wei SH. Treatment response to maxillary expansion and protraction. *Eur J Orthod* 1996;18: 151-68.
27. Ngan PW, Hägg U, Yiu C, Wei SH. Treatment response and long-term dentofacial adaptations to maxillary expansion and protraction. *Semin Orthod* 1997;3:255-64.
28. Hägg U, Tse A, Bendeus M, Rabie AB. Long-term follow-up of early treatment with reverse headgear. *Eur J Orthod* 2003;25: 95-102.
29. Haas AJ. Palatal expansion: just the beginning of dentofacial orthopedics. *Am J Orthod* 1970;57:219-55.
30. Richardson A. Early treatment of pseudo Class III malocclusion in mixed dentition [abstract]. *Br Dent J* 1999;186:177.
31. Oppenheim A. A possibility for physiologic orthodontic movement. *Am J Orthod* 1944;30:277-328.
32. Sugawara J, Asano T, Endo N, Mitani H. Long-term effects of chin-cap therapy on skeletal profile in mandibular prognathism. *Am J Orthod Dentofacial Orthop* 1990;98:127-33.
33. Mitani H. Early application of chin-cap therapy to skeletal Class III malocclusion. *Am J Orthod Dentofacial Orthop* 2002;121: 584-5.
34. Deguchi T, Kuroda T, Minoshima Y, Graber TM. Craniofacial features of patients with Class III abnormalities: growth-related changes and effects of short-term and long-term chin-cap therapy. *Am J Orthod Dentofacial Orthop* 2002;121:84-92.
35. Dietrich UC. Morphological variability of skeletal Class III relationships as revealed by cephalometric analysis. *Trans Europe Orthod Soc* 1970;46:131-43.
36. Kettle MA, Burnapp DR. Occipito-mental anchorage in the orthodontic treatment of dental deformities due to cleft lip and palate. *Br Dent J* 1955;99:11-4.
37. Delaire J. L'articulation fronto-maxillaire: bases theoretiqes et principes generaux d'application de forces extra-orales postero-anterieures sur masque orthopedique. *Rev Stomat Paris* 1976;77:921-30.
38. Dellinger EL. A preliminary study of anterior maxillary displacement. *Am J Orthod* 1973;63:509-16.
39. Jackson GW, Kokich VG, Shapiro PA. Experimental and post-experimental responses to anteriorly directed extraoral force in young macaca nemestrina. *Am J Orthod* 1979;75:318-33.
40. Kambara T. Dentofacial changes produced by extraoral forward force in the macaca irus. *Am J Orthod* 1977;71:249-77.
41. Nanda R, Hickory W. Zygomaticomaxillary suture adaptations incident to anteriorly-directed forces in rhesus monkeys. *Angle Orthod* 1984;54:199-210.
42. McNamara JA Jr. An orthopedic approach to the treatment of Class III malocclusion in young patients. *J Clin Orthod* 1987; 21:598-608.
43. Turley PK. Orthopedic correction of Class III malocclusion with palatal expansion and custom protraction headgear. *J Clin Orthod* 1988;22:314-25.
44. Irie M, Nakamura S. Orthopedic approach to severe skeletal Class III malocclusion. *Am J Orthod* 1975;67:377-92.
45. Ishii H, Morita S, Takeuchi Y, Nakamura S. Treatment effect of combined maxillary protraction and chin-cap appliance in severe skeletal Class III cases. *Am J Orthod Dentofacial Orthop* 1987; 92:304-12.
46. Takada K, Petdachai S, Sakuda M. Changes in dentofacial morphology in skeletal Class III children treated by a modified maxillary protraction headgear and a chin cup: a longitudinal cephalometric appraisal. *Eur J Orthod* 1993;15:211-21.
47. Wisth PJ, Tritapunt A, Rygh P, Boe OE, Norderval K. The effect of maxillary protraction on front occlusion and facial morphology. *Acta Odontol Scand* 1987;45:227-37.
48. Baccetti T, McGill JS, Franchi L, McNamara JA Jr, Tollaro I. Skeletal effects of early treatment of Class III malocclusion with maxillary expansion and face-mask therapy. *Am J Orthod Dentofacial Orthop* 1998;113:333-43.
49. Sarver DM, Johnston MW. Skeletal changes in vertical and anterior displacement of the maxilla with bonded rapid palatal expansion. *Am J Orthod Dentofacial Orthop* 1989;95:462-6.
50. Williams MD, Sarver DM, Sadowsky PL, Bradley E. Combined rapid maxillary expansion and protraction facemask in the treatment of Class III malocclusions in growing children: a prospective long term study. *Semin Orthod* 1997;3:265-74.
51. Liou EJ. Effective maxillary orthopedic protraction for growing Class III patients: a clinical application simulating distraction osteogenesis. *Prog Orthod* 2005;6:154-71.
52. Liou EJ. Toothborne orthopedic maxillary protraction in Class III patients. *J Clin Orthod* 2005;39:68-75.
53. Yilmaz BS, Kucukkeles N. Skeletal, soft tissue, and airway changes following the alternate maxillary expansions and constrictions protocol. *Angle Orthod* 2014;84:868-77.
54. Cevdanes L, Baccetti T, Franchi L, McNamara JA Jr, De Clerck H. Comparison of two protocols for maxillary protraction: bone anchors versus face mask with rapid maxillary expansion. *Angle Orthod* 2010;80:799-806.
55. Wilmes B, Ngan P, Liou EJ, Franchi L, Drescher D. Early Class III facemask treatment with the hybrid hyrax and Alt-RAMEC protocol. *J Clin Orthod* 2014;48:84-93.
56. Westwood PV, McNamara JA Jr, Baccetti T, Franchi L, Sarver DM. Long-term effects of Class III treatment with rapid maxillary expansion and facemask therapy followed by fixed appliances. *Am J Orthod Dentofacial Orthop* 2003;123:306-20.
57. Wang A, Ngan P, Martin CA, Razmus T, Tremont T, Musich D, et al. Treatment outcomes of stable and unstable Class III patients [abstract 184112]. *J Dent Res* 2014.
58. Harzer W, Schneider M, Gedrange T. Rapid maxillary expansion with palatal anchorage of the hyrax expansion screw—pilot study with case presentation. *J Orofac Orthop* 2004;65:419-24.
59. Tausche E, Hansen L, Schneider M, Harzer W. Bone-supported rapid maxillary expansion with an implant-borne hyrax screw: the Dresden distractor. *Orthod Fr* 2008;79:127-35.
60. MacGinnis M, Chu H, Youssef G, Wu KW, Machado AW, Moon W. The effects of micro-implant assisted rapid palatal expansion (MARPE) on the nasomaxillary complex—a finite element method (FEM) analysis. *Prog Orthod* 2014;15:52.
61. Carlson C, Sung J, McComb R, Machado AW, Moon W. The use of a micro-implant assisted rapid palatal expansion appliance to orthopedically correct transverse maxillary deficiency in an adult patient. *Am J Orthod Dentofacial Orthop* 2015 (in press).
62. Machado AW, Briss B, Huang GJ, Kulbersh R, Caldas SG. An interview with Won Moon. *Dental Press J Orthod* 2013;18:12-28.
63. Moon W, Khullar R. Class III orthopedic treatment with skeletal anchorage. In: Ngan P, Deguchi T, Roberts EW, editors. *Orthodontic treatment of Class III malocclusion*. Sharjah, UAE: Bentham Science Publisher Ltd; 2014. p. 116-50.
64. Lee NK, Yang IH, Baek SH. The short-term treatment effects of face mask therapy in Class III patients based on the anchorage

- device: miniplates vs rapid maxillary expansion. *Angle Orthod* 2012;82:846-52.
65. Hino CT, Cevidanes LH, Nguyen TT, De Clerck HJ, Franchi L, McNamara JA Jr. Three-dimensional analysis of maxillary changes associated with facemask and rapid maxillary expansion compared with bone anchored maxillary protraction. *Am J Orthod Dentofacial Orthop* 2013;144:705-14.
 66. Wu KW, MacGinnis M, Sung J, Chu H, Youssef G, Machado AW, et al. The efficacy of maxillary protraction protocols with and without micro-implants—a finite element study. *Prog Orthod* 2015 (in press).
 67. Moss ML. A theoretical analysis of the functional matrix. *Acta Biotheor* 1968;18:195-202.
 68. Moss ML. Functional cranial analysis and the functional matrix. *Int J Orthod* 1979;17:21-31.
 69. Moss ML. The functional matrix hypothesis revisited. 1. The role of mechanotransduction. *Am J Orthod Dentofacial Orthop* 1997; 112:8-11.
 70. Moss ML. The functional matrix hypothesis revisited. 2. The role of an osseous connected cellular network. *Am J Orthod Dentofacial Orthop* 1997;112:221-6.
 71. Moss ML. The functional matrix hypothesis revisited. 3. The genomic thesis. *Am J Orthod Dentofacial Orthop* 1997;112: 338-42.
 72. Moss ML. The functional matrix hypothesis revisited. 4. The epigenetic antithesis and the resolving synthesis. *Am J Orthod Dentofacial Orthop* 1997;112:410-7.
 73. De Clerck H, Cevidanes L, Baccetti T. Dentofacial effects of bone-anchored maxillary protraction: a controlled study of consecutively treated Class III patients. *Am J Orthod Dentofacial Orthop* 2010;138:577-81.
 74. Baccetti T, De Clerck HJ, Cevidanes LH, Franchi L. Morphometric analysis of treatment effects of bone-anchored maxillary protraction in growing Class III patients. *Eur J Orthod* 2011;33: 121-5.
 75. Hong C, Lee H, Webster R, Kwak J, Wu BM, Moon W. Stability comparison between commercially available designs and a novel design: part 1. *Angle Orthod* 2011;81:692-9.
 76. Hong C, Truong P, Song HN, Wu BM, Moon W. Mechanical stability assessment of novel orthodontic mini-implant designs: part 2. *Angle Orthod* 2011;81:1001-9.
 77. Song HN, Hong C, Banh R, Ohebsion T, Asatrian G, Leung HY, et al. Mechanical stability and clinical applicability assessment of novel orthodontic mini-implant design: part 3. *Angle Orthod* 2013;83:832-41.
 78. Rey D, Aristizabal JF, Oberti G, Angel D. Mandibular cervical headgear in orthopedic and orthodontic treatment of Class III cases. *World J Orthod* 2006;7:165-76.
 79. Kim YH. Anterior openbite and its treatment with multiloop edgewise archwire. *Angle Orthod* 1987;57:290-321.
 80. He S, Gao J, Wamalwa P, Wang Y, Zou S, Chen S. Camouflage treatment of skeletal Class III malocclusion with multiloop edgewise arch wire and modified Class III elastics by maxillary mini-implant anchorage. *Angle Orthod* 2013;83: 630-40.
 81. Ngan PW, Sung JH. Treatment strategies for developing and non-developing Class III malocclusions. In: Nanda R, editor. *Esthetics and biomechanics in orthodontics*. 2nd ed. Philadelphia: Elsevier; 2015. p. 246-92.
 82. Sakthi SV, Vikraman B, Shobana VR, Iyer SK, Krishnaswamy NR. Corticotomy-assisted retraction: an outcome assessment. *Indian J Dent Res* 2014;25:748-54.
 83. Trauner R, Obwegeser H. The surgical correction of mandibular prognathism and retrognathia with consideration of genioplasty. *Oral Surg Oral Med Oral Pathol* 1957;10: 677-89.
 84. Epker BN, Wolford LM. Middle third facial osteotomies: their use in the correction of acquired and developmental dentofacial and craniofacial deformities. *J Oral Surg* 1975;33: 491-514.
 85. Crago CA, Proffit WR, Ruiz RL. Maxillofacial distraction osteogenesis. In: Proffit WR, White RP, Sarver DM, editors. *Contemporary treatment of dentofacial deformity*. St Louis: Mosby; 2003. p. 357-93.
 86. Figueroa AA, Polley JW. Management of severe cleft maxillary deficiency with distraction osteogenesis: procedure and results. *Am J Orthod Dentofacial Orthop* 1999; 115:1-12.
 87. Aksu M, Saglam-Aydinatay B, Akcan CA, El H, Taner T, Kocadereli I, et al. Skeletal and dental stability after maxillary distraction with a rigid external device in adult cleft lip and palate patients. *J Oral Maxillofac Surg* 2010;68:254-9.
 88. Iida S, Yagi T, Yamashiro T, Okura M, Takada K, Kogo M. Maxillary anterior segmental distraction osteogenesis with the dynam system for severe maxillary retrusion in cleft lip and palate. *Plastic Reconstr Surg* 2007;120:508-16.
 89. Farret MM, Benitez. Skeletal class III malocclusion treated using a non-surgical approach supplemented with mini-implants: a case report. *J Orthod* 2013;40:256-63.
 90. Gurgel JA, Tiago CM, Normando D. Transverse changes after surgically assisted rapid palatal expansion. *Int J Oral Maxillofac Surg* 2014;43:316-22.
 91. Byloff FK, Mossaz CF. Skeletal and dental changes following surgically assisted rapid palatal expansion. *Eur J Orthod* 2004;26: 403-9.
 92. Chung CH, Goldman AM. Dental tipping and rotation immediately after surgically assisted rapid palatal expansion. *Eur J Orthod* 2003;25:353-8.
 93. Semb G. A study of facial growth in patients with unilateral cleft lip and palate treated by the Oslo CLP Team. *Cleft Palate Craniofac J* 1991;28:1-21; discussion 46-48.
 94. Liou EJ, Chen PH, Wang YC, Yu CC, Huang CS, Chen YR. Surgery-first accelerated orthognathic surgery: orthodontic guidelines and setup for model surgery. *J Oral Maxillofac Surg* 2011;69: 771-80.
 95. Sharma VK, Yadav K, Tandon P. An overview of surgery-first approach: recent advances in orthognathic surgery. *J Orthod Sci* 2015;4:9-12.
 96. Hernández-Alfaro F, Guijarro-Martínez R, Peiró-Guijarro MA. Surgery first in orthognathic surgery: what have we learned? A comprehensive workflow based on 45 consecutive cases. *J Oral Maxillofac Surg* 2014;72:376-90.
 97. Leelasingjaroen P, Godfrey K, Manosudprasit M, Wangsrimongkol T, Surakunprapha P, Pisek P. Surgery first orthognathic approach for skeletal Class III malocclusion corrections—a literature review. *J Med Assoc Thai* 2012;95(Suppl 11): S172-80.
 98. Park SH, Yu HS, Kim KD, Lee KJ, Baik HS. A proposal for a new analysis of craniofacial morphology by 3-dimensional computed tomography. *Am J Orthod Dentofacial Orthop* 2006;129: 600.e23-34.
 99. Wong RW, Chau AC, Hägg U. 3D CBCT McNamara's cephalometric analysis in an adult Southern Chinese population. *Int J Oral Maxillofac Surg* 2011;40:920-5.

100. Marcus JR, Domeshek LF, Das R, Marshall S, Nightingale R, Stokes TH, et al. Objective three-dimensional analysis of cranial morphology. *Eplasty* 2008;8:e20.
101. Moon W. A numerical and visual approach for measuring the effects of functional appliance therapy: fourier descriptors. In: Lestrel PE, editor. *Fourier descriptors and their applications in biology*. New York: Cambridge University Press; 1997.
102. Lestrel PE, Wolfe C. Size and shape of the rabbit orbit: 3-D Fourier descriptors. In: Lestrel PE, editor. *Fourier descriptors and their applications in biology*. New York: Cambridge University Press; 1997.
103. Khullar R, Moon W, Wolfe CA. Representation of the mandible as a curve in 3-space: a preliminary study using Fourier descriptors. *Proceedings of the Second International Symposium of Biological Shape Analysis*; 2013 Sept 7-9; Okinawa, Japan. Singapore: World Scientific; 2013.
104. Gutman B, Sung J, Moon W, Thomson PM. Robust shape correspondence via spherical patch matching for atlases of partial skull models. In: Levine JA, Paulsen RR, Zhang YJ, editors. *Mesh processing in medical image analysis*. New York: Springer; 2012. p. 89-100.
105. Baik HS, Lee HJ, Lee KJ. A proposal for soft tissue landmarks for craniofacial analysis using 3-dimensional laser scan imaging. *World J Orthod* 2006;7:7-14.
106. Lin HH, Lo LJ. Three-dimensional computer-assisted surgical simulation and intraoperative navigation in orthognathic surgery: a literature review. *J Formos Med Assoc* 2015;114: 300-7.
107. Nanda V, Gutman B, Bar E, Alghamdi S, Tetradis S, Lusic AJ, Eskin E, Moon W. Quantitative analysis of 3-dimensional facial soft tissue photographic images: technical methods and clinical application. *Prog Orthod* 2015 (in press).

Nostalgia Advertisement from a 1937 issue of the Journal

Chewing Gum—GOOD FOR
KINDERGARTEN AGES, UP

Among the staunch chewing gum advocates are orthodontists and investigators of various phases of preventive and operative dentistry. We are told that chewing gum after meals is a dependable help in cleansing teeth and that the chewing exercise helps stimulate circulation in the gums.



R-35

NATIONAL ASSOCIATION OF
 CHEWING GUM MANUFACTURERS
 ROSESANK, STATEN ISLAND, NEW YORK